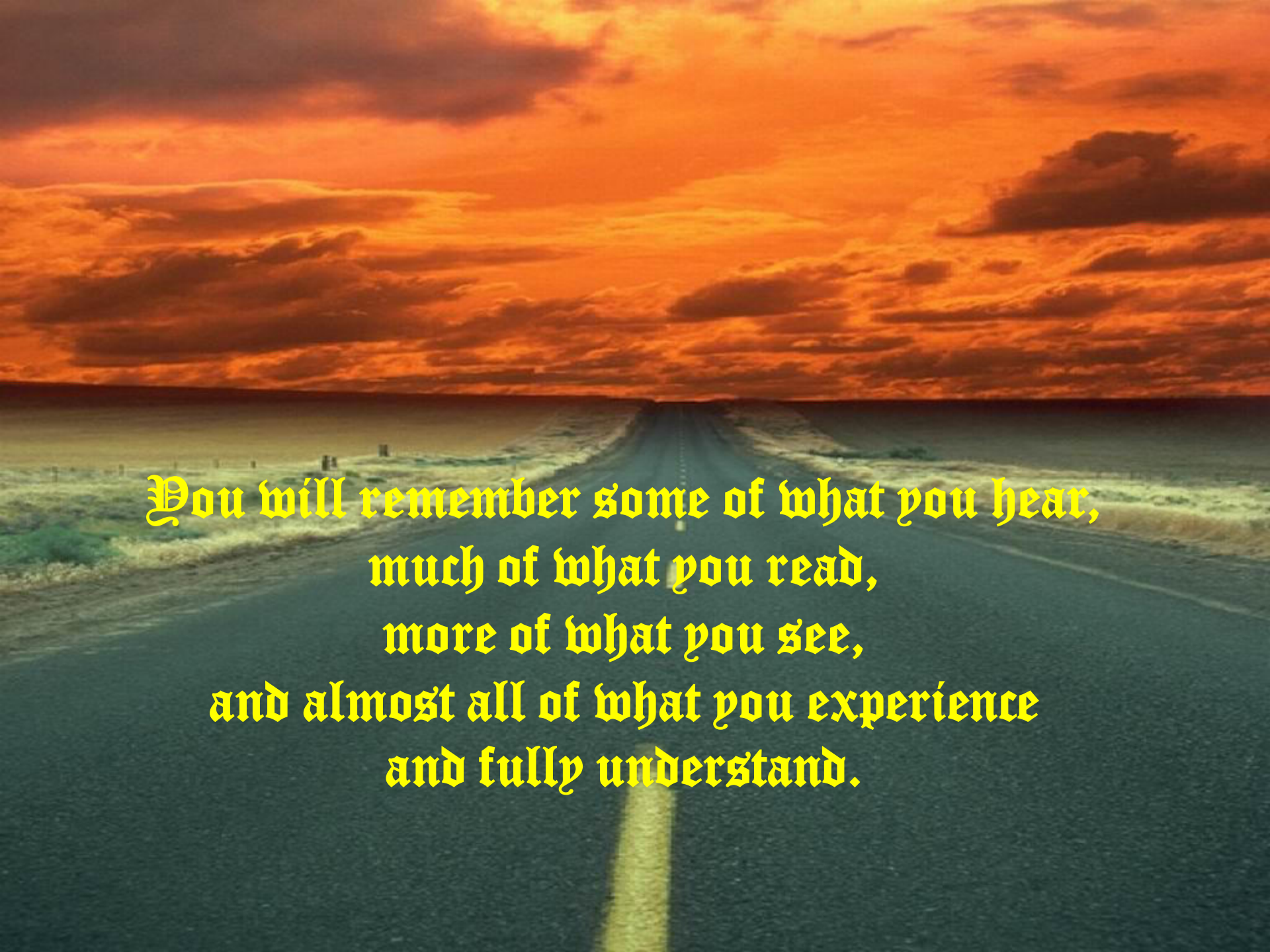
You will remember some of what you hear,
much of what you read,
more of what you see,
and almost all of what you experience
and fully understand.

Examination and Diagnosis of Pain

INTRODUCTION

- Greek ”Poin”; meaning penalty.
- “Poena”; meaning punishment from God
- International association for study of pain defined pain as

  “An unpleasant sensory or emotional experience associated with actual or potential tissue damage or described in terms of such damage”

NEUROANATOMY

- Neuron
- Afferent / sensory fibers
- Efferent / motor fibers
- First order neuron
- Second order neuron
- Third order neuron
- Internuncial neuron

NEURAL PATHWAYS

Given by Fields-1987

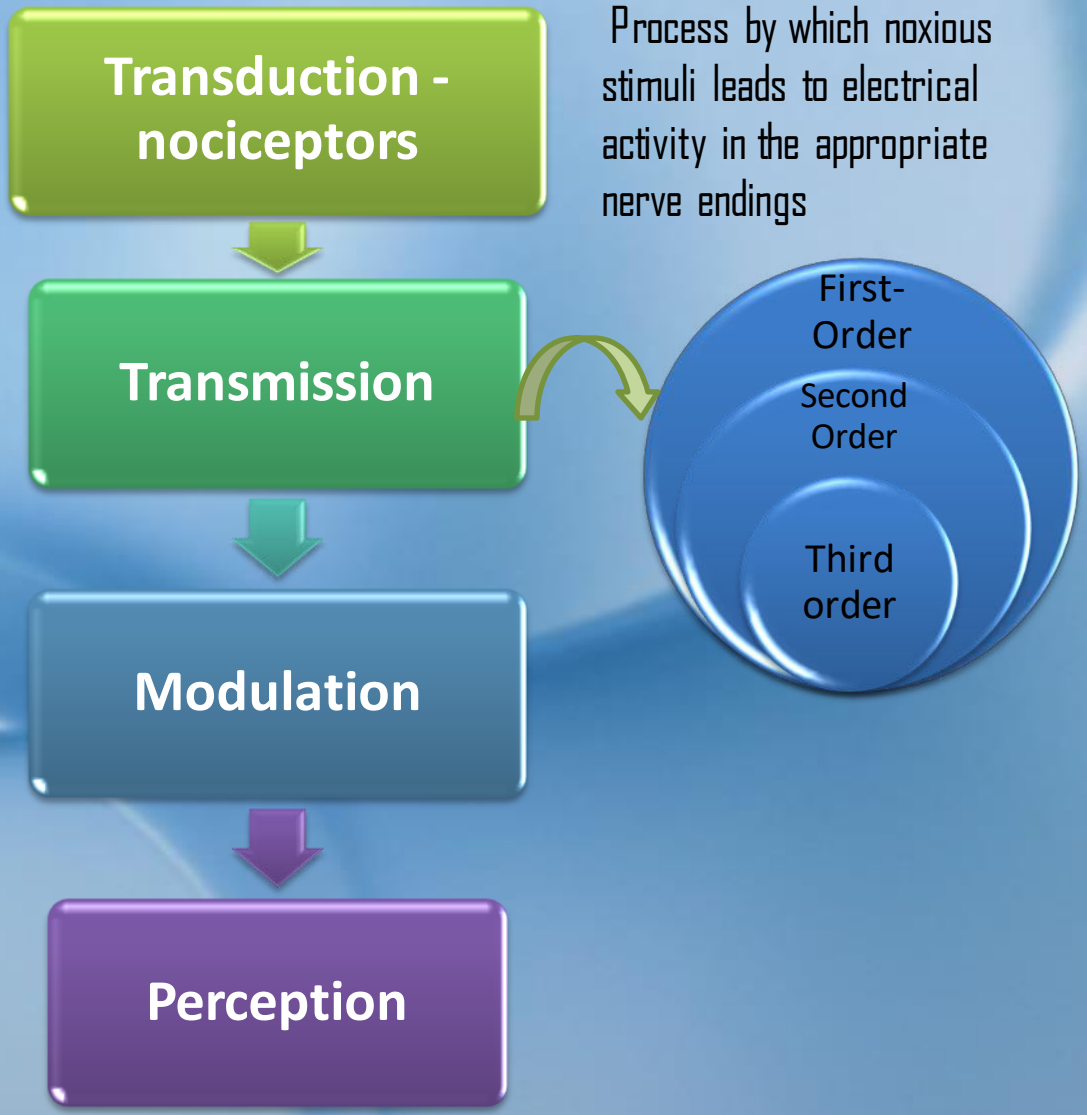

Process by which noxious stimuli leads to electrical activity in the appropriate nerve endings

Ability of the CNS to control the pain transmitting neurons

SENSORY RECEPTORS

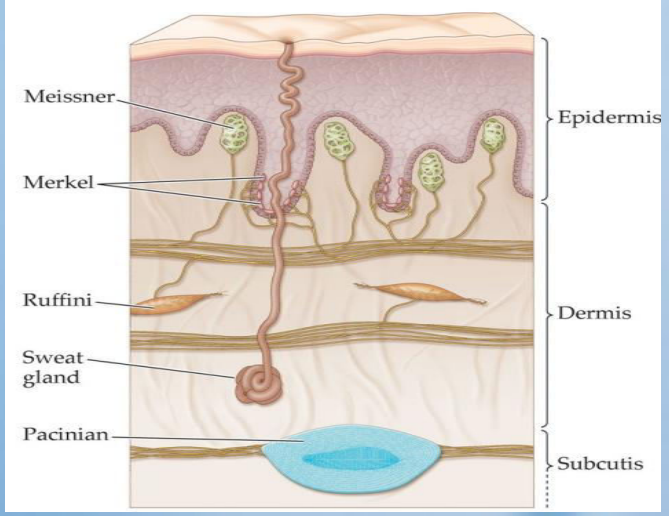

EXTERORECEPTORS

- MEISSNER'S CORPUSCULES
- MERCKEL'S
- RUFFININ'S
- KRAUSE'S
- FREE NERVE ENDINGS

PROPRIORECEPTORS

- MUSCLE SPINDLES
- GOLGI TENDON
- PACINIAN CORPUSCULES
- PERIODONTAL MECHANORECEPTORS
- FREE NERVE ENDINGS

INTEROCEPTORS

- PACINIAN CORPUSCLES
- FREE NERVE ENDINGS

NOCIRECEPTORS

- A nerve ending that responds to noxious stimuli that can actually or potentially produce tissue damage.

- Free nerve endings

- By:
  - thermal
  - mechanical
  - chemical
  - tissue damage

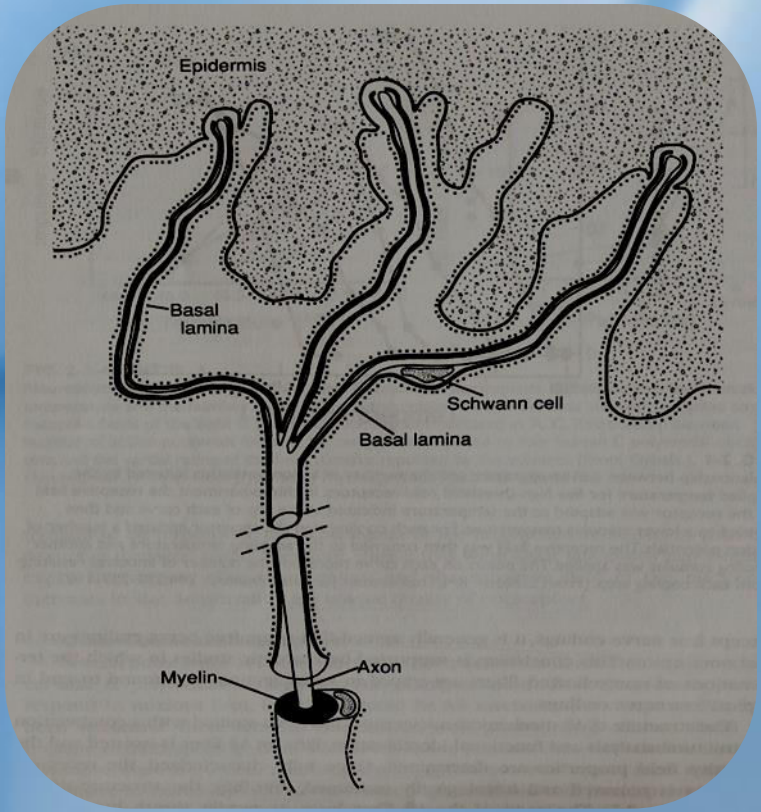

- **TYPES OF NOCICEPTORS**

- Aδ Mechanical Nociceptors
- C Polymodal Nociceptors
- High threshold mechanoreceptive nociceptors

- **RECEPTOR MECHANISM**

- Noxious stimuli
- Tissue damage chemicals

PAIN FIBERS

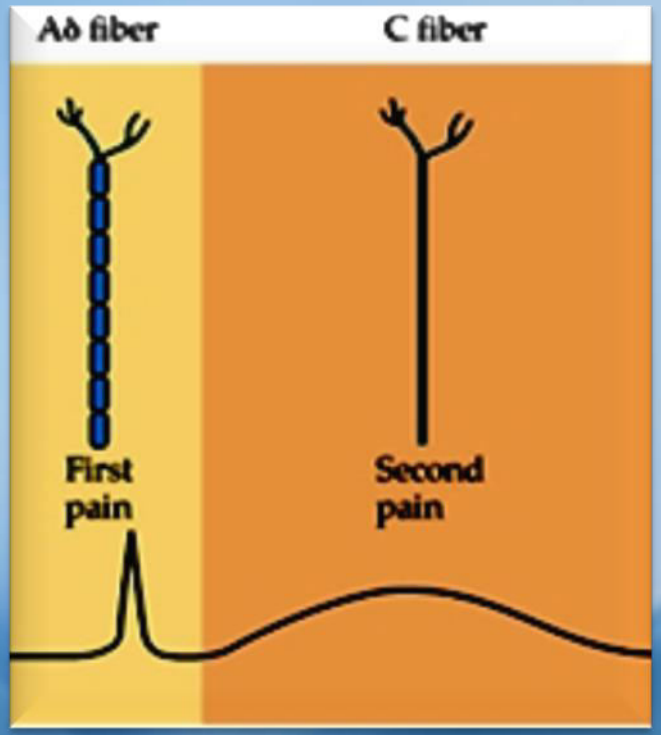

Fast conduction

Throbbing pain

Slow conduction

Dull aching pain

- Fast pain : 0.1 second ,sharp, pricking, acute, and electric pain. Not felt in most deeper tissue or the body

- Slow pain : 1 second ,

-slow burning pain, aching, throbbing pain, nauseous pain, and chronic pain.

-associated with tissue destruction.

-prolonged, unbearable suffering.

-both in the skin and in almost any deep tissue or organ.

TRIGEMINAL SYSTEM

Afferent impulses from Aδ & C fibers from the periphery

⇩

Gasserian ganglion

⇩

Enter pons & descend in Trigeminal tract to enter trigeminal nucleus

(1) the subnucleus oralis,
(2) the subnucleus interpolaris
(3) the subnucleus caudalis,

⇩

Second-order neurons (WDR, NS)

⇩

thalamus

⇩

Cerebral cortex

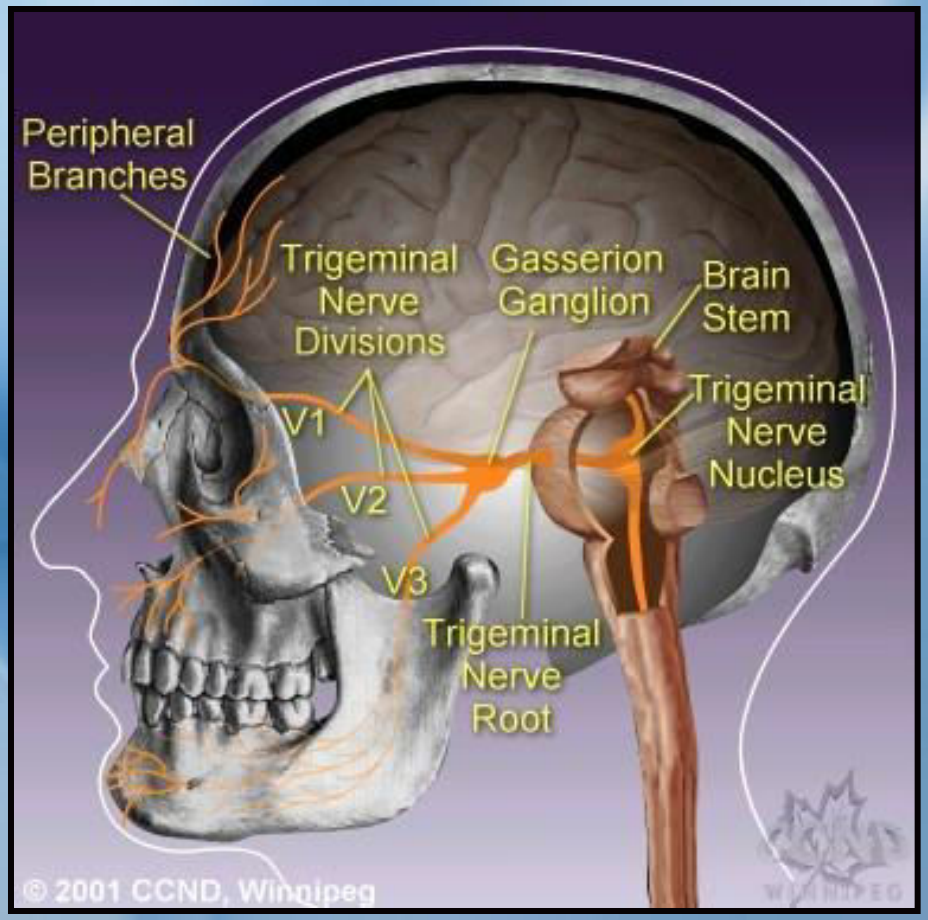

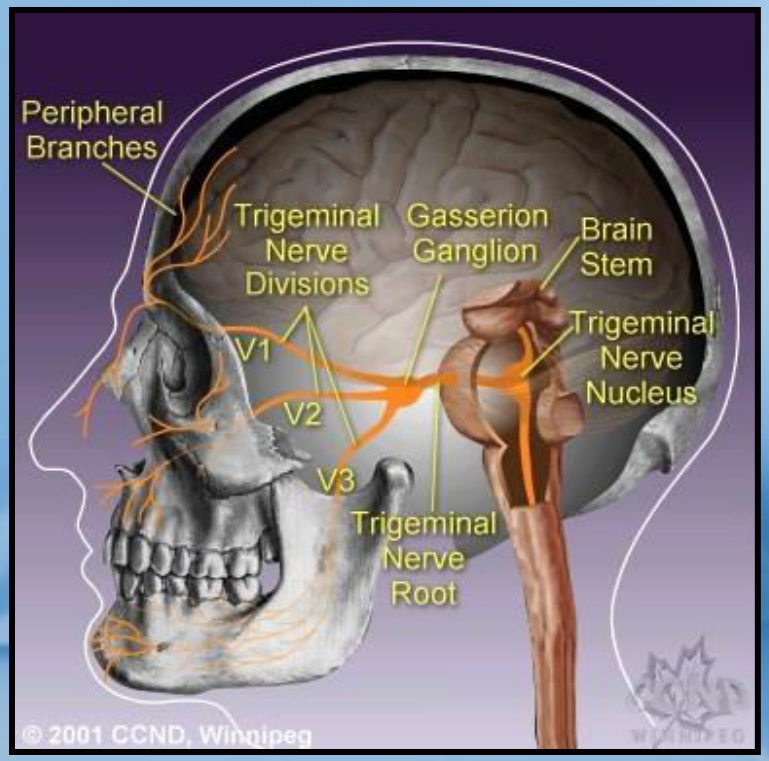
Peripheral Branches
Trigeminal Nerve Divisions
Gasserion Ganglion
Brain Stem
Trigeminal Nerve Nucleus
V1
V2
V3
Trigeminal Nerve Root
© 2001 CCND, Winnipeg

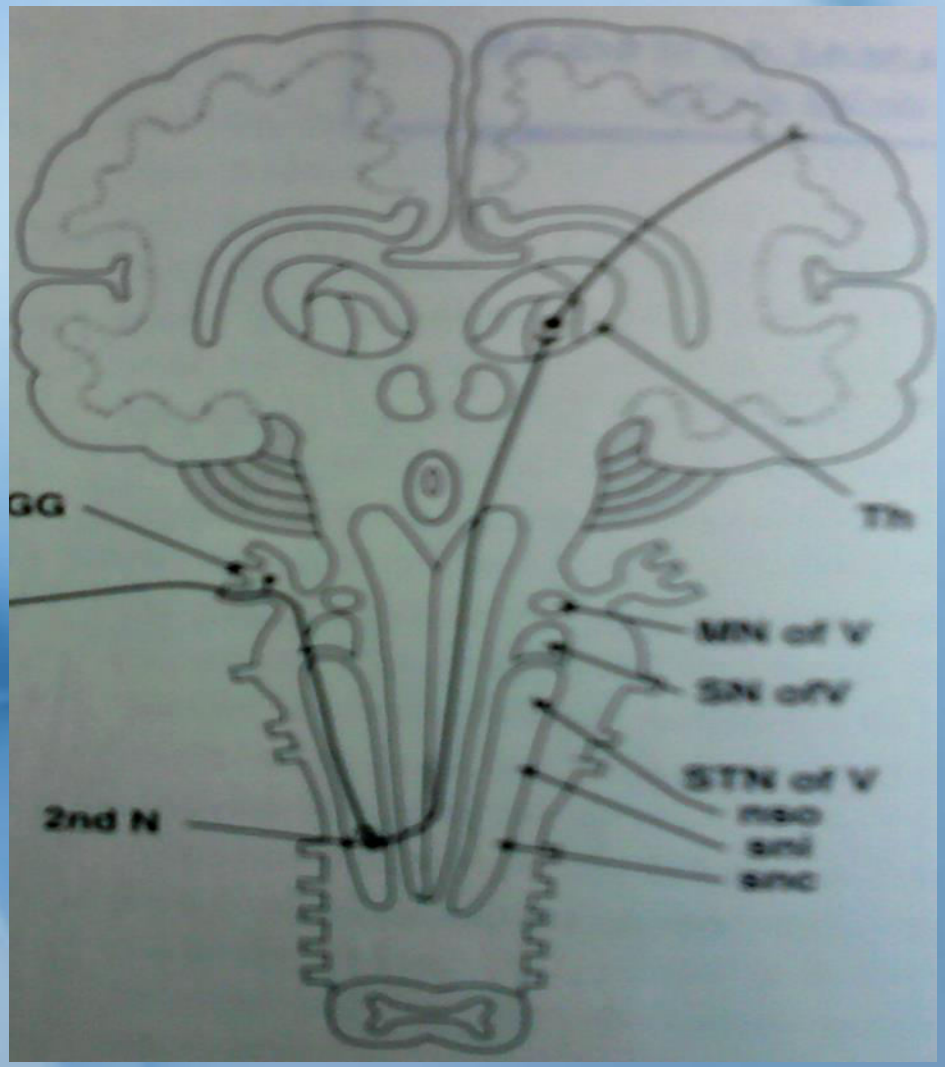
GG
Th
MN of V
SN of V
STN of V
2nd N

THEORIES OF PAIN

- Specificity theory
- Pattern theory
- Gate Control theory

Gate Control theory

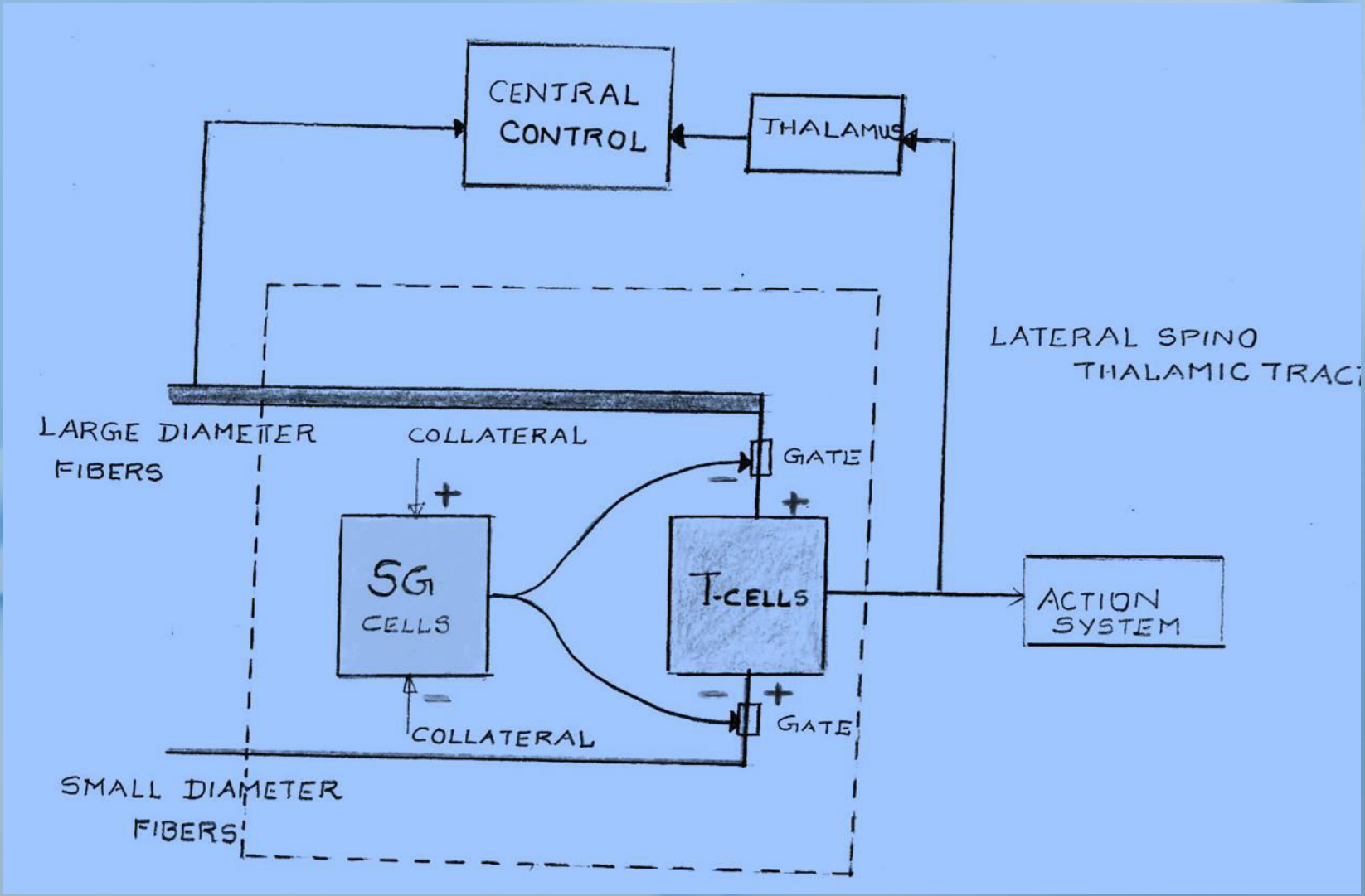

TYPES OF HETEROTROPHIC PAIN

CENTRAL PAIN	PROJECTED PAIN	REFERRED PAIN
• Pain emanates from structures of CNS is felt peripherally	• It is felt In the peripheral distribution of same nerve that mediate the primary nociceptive input	• Spontaneous heterotopic pain

REFERRED PAIN

- Visceral pain is often referred,
- Referred pain is felt at the dermatome which corresponds to the viscerotome of the pain producing viscus

RULES:

- Occurs within single nerve root, passing from 1 branch to other- follows *dermatome* pattern
- Rarely crosses midline, unless originates there.
- If RP is felt outside the nerve that mediates pain, it is generally felt cephalad to the nerve and not caudally.

THE PHENOMENON OF REFERRAL

- Convergence

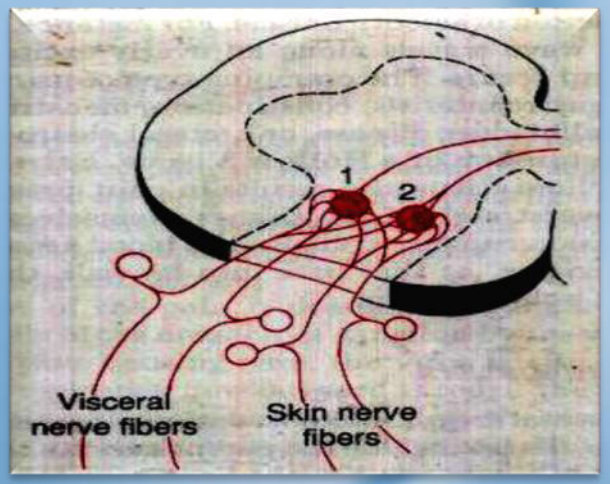

- lung pain is not referred although lung is a viscus.
- visceral pain may also be felt in the local region
- the referred site may be an unusual site. Thus, cardiac pain may be felt at the neck/angle of jaw/epigastrium.

- Teeth – common sources of referred pain
- Endings of VII, IX and X nerves are diffusely distributed with in subnucleus caudalis

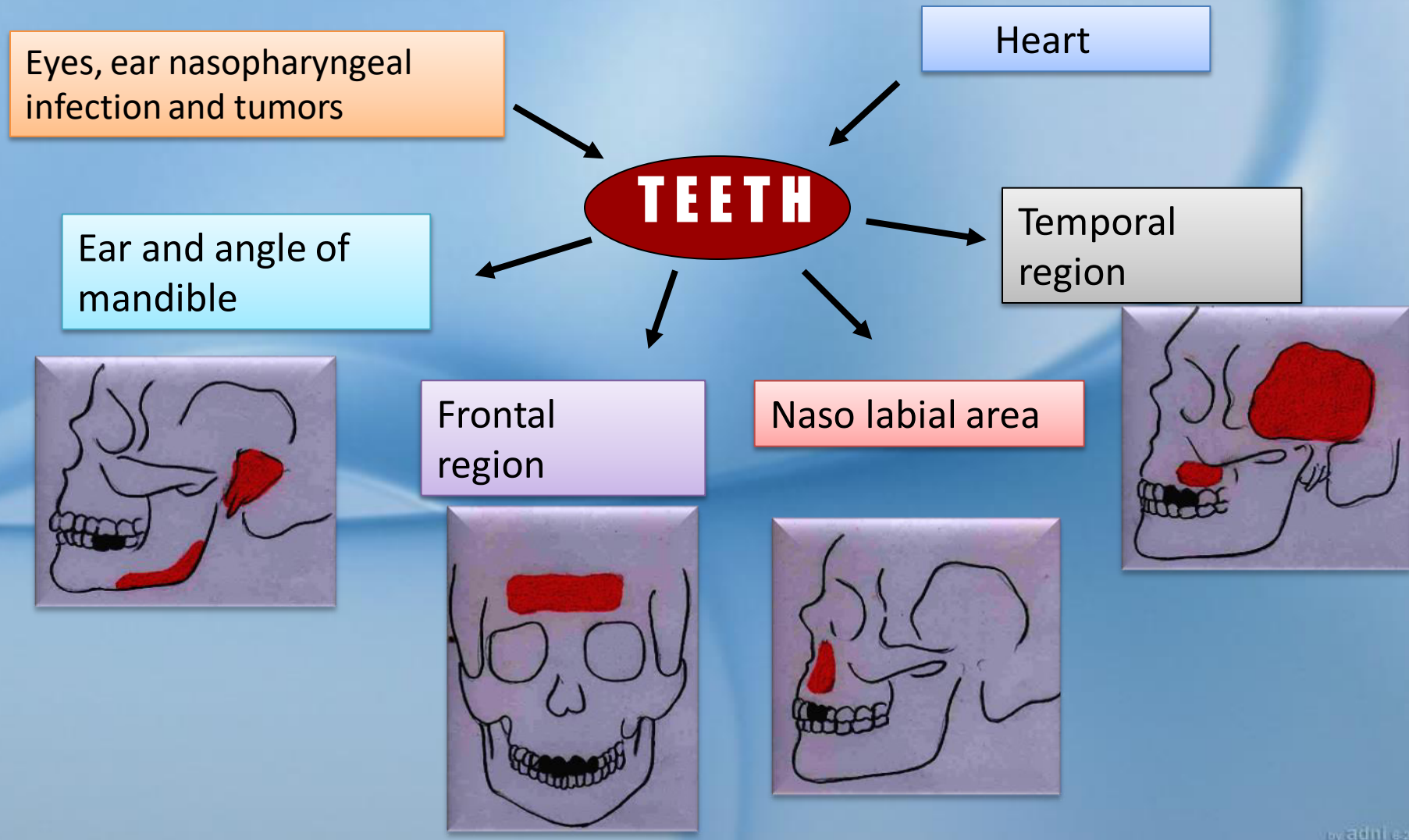

HISTORY

- Location
- onset
- Characteristics
- Concomitant symptoms
- Aggravating and Relieving factors

LOCATION

- Localized / diffuse
- Unilateral / bilateral
- Non anatomic in distribution & pain jumps from tooth to tooth – psychogenic pain

Maxilla	• Sinusitis, lesions in maxillary sinus • odontalgia & trigeminal neuralgia
Mandible	• Odontalgia, trigeminal & glossopharyngeal neuralgia • Referred of cardiac & subacute thyroiditis
cervical	• Tension headache, arthritis • Eagle's syndrome, carotidynia
Nasal/paranasal	trigeminal & glossopharyngeal neuralgia & sinusitis
Frontal / temporal	Vascular headache, postherpetic neuralgia & TMD

ONSET

- SPONTANEOUS : pain occurs without being evoked
- INDUCED : when some provocation causes the painful sensation.
- TRIGGERED : when evoked response is out of proportion to the stimulus.

CHARACTERISTICS

QUALITY

- Steady pain – it flows as an unpleasant sensation
- Paroxysmal pain – sudden attack or outburst of pain
- Pricking – sharp intermittent character of short duration & tingling pain
- Itching – superficial discomfort with a subthreshold pain.
- Stinging increased intensity of superficia
- Aching deep discomfort & it is more continuous
- Burning – the discomfort has a hot, raw,



BEHAVIOUR

TEMPORAL

- Intermittent
- Continuous
- Recurrent

DURATION

- Momentary
- Protracted
- Intractable

LOCALIZATION

- Localized pain – define an exact anatomical location
- Diffuse pain – pain is less well defined & somewhat vague & variable
- Radiating pain – rapidly changing pain
- Lancinating pain – a momentary cutting exacerbation
- Spreading pain – more gradually changing pain
- Enlarging pain – progressively involves the adjacent anatomic areas
- Migrating pain – changes from one location to other

INTENSITY OF PAIN

PAIN ASSESSMENT TOOLS

- Visual analog scales
- Verbal rating scale
- Numeric rating scale
- Faces pain scale
- McGill pain Questionnaire

Visual Analog Scales:

- A visual analog scale is a line that represents a continuum of a particular experience, such as pain.
- No Pain → Worst Pain Imaginable

Simple descriptive scale or verbal rating scale

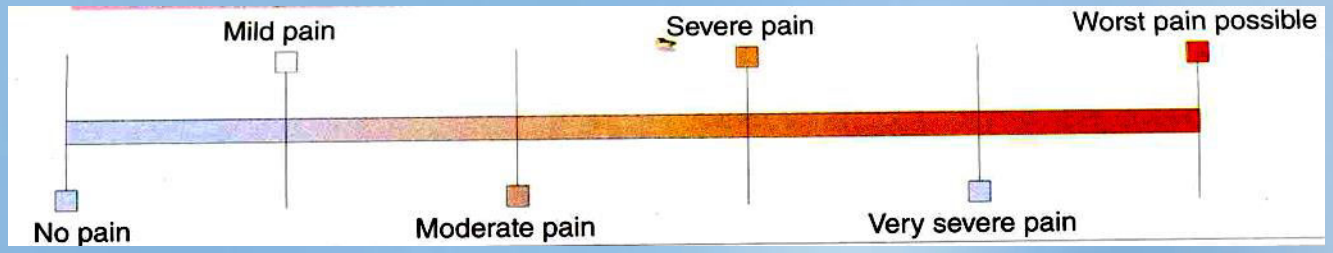

Numeric rating scale

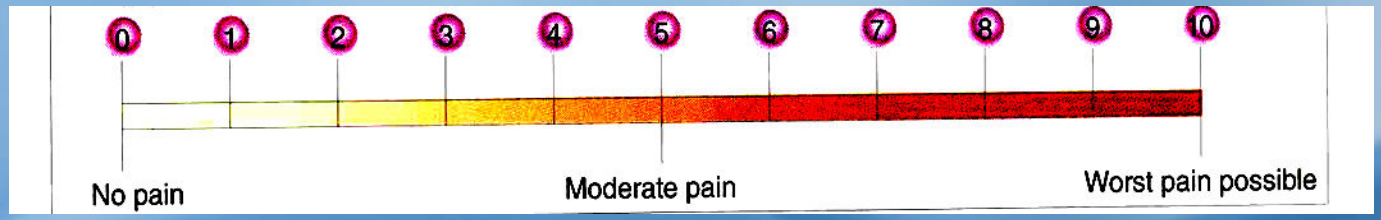

Faces pain scale

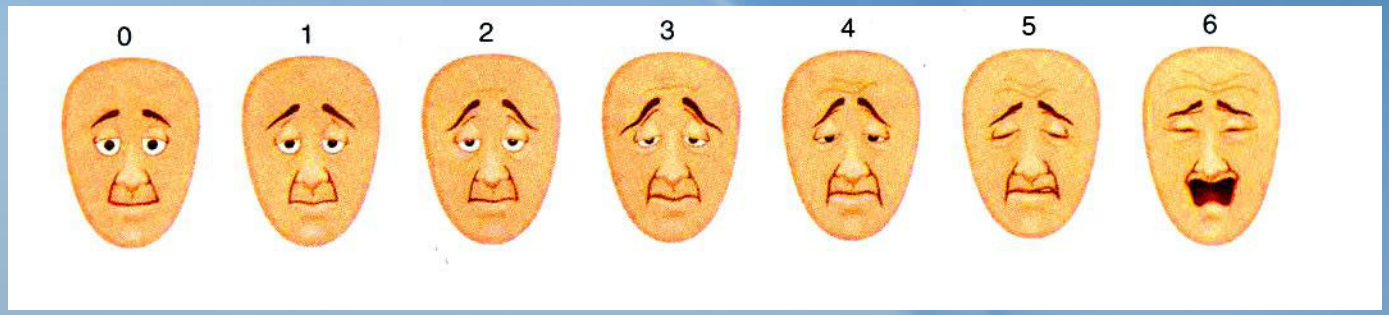

McGill Pain Questionnaire:

- The McGill pain questionnaire is a verbal pain scale that uses a vast array words commonly used to describe a pain experience.

- Patients use different words to describe the affective component of their pain.

- To facilitate the use of these words in a systematic way, Melzack and Togerson set about categorizing many of these verbal descriptors into classes and subclasses designed to describe these different aspects of the pain experience.

Sensory				
1 Flickering Quivering Pulsing Throbbing Beating Pounding	2 Jumping Flashing Shooting	3 Pricking Boring Drilling Stabbing Lancinating	4 Sharp Cutting Lacerating	5 Pinching Pressing Gnawing Cramping Crushing
6 Tugging Pulling Wrenching	7 Hot Burning Scalding Searing	8 Tingling Itchy Smarting Stinging	9 Dull Sore Hurting Aching Heavy	10 Tender Taut Rasping Splitting
Affective				
11 Tiring Exhausting	12 Sickening Suffocating	13 Fearful Frightful Terrifying	14 Punishing Gruelling Cruel Vicious Killing	15 Wretched Blinding
Evaluative	**Miscellaneous**			
16 Annoying Troublesome Miserable Intense	17 Spreading Radiating Penetrating Piercing	18 Tight Numb Drawing Squeezing Tearing	19 Cool Cold Freezing	20 Nagging Nauseating Agonizing Dreadful Torturing

CONCOMITANT SYMPTOMS

- Sensory, motor and autonomic effects that accompany the pain , included

- Changes in the special senses

AGGRAVATING & RELIEVING FACTORS

- Effect of functional activities
- Effect of physical modalities
- Medications
- Emotional stress

Psychological Assessment

- As the pain is chronic, the psychological factors will accompany.
- Measuring tools to assess the psychological status of the patient:
  - Multidimensional pain Inventory (MPI)
  - Symptom check list 90 (SCL-90)
  - TMJ scale

EXAMINATION

GENERAL EXAMINATION

- VITAL SIGNS:
  - In some instances it may prove to be a major contributor to the pain
  - Rapid pulse : anxious / nervous patient
  - Increase body temperature : systemic infections
  - Hypertension : certain Headaches
  - Increased breathing rate : up-regulation of the sympathetic nervous system

CRANIAL NERVE EXAMINATION

CRANIAL NERVE	FUNCTION	USUAL COMPLAINT	TEST OF FUNCTION	PHYSICAL FINDINGS
Olfactory Nerve	Smell	None or loss of “taste” if bilateral	Sense of smell with each nostril	No response to olfactory stimuli
Optic Nerve	Vision	Loss of vision	Visual acuity Visual fields of ach eye	Decreased visual acuity or loss of visual field
Oculomotor nerve	Eye movement Pupillary constriction	D	upil and novemen	
Trochlear nerve	Eye movement	Double vision, especially on down and medial gaze	Ability to eye down	
Trigeminal nerve	Facial, nasal, and oral sensation Jaw movement	Numbness paresthesia	Light touch and pinprick sensatio face Corneal reflex Masseter contrac	and reflex scles

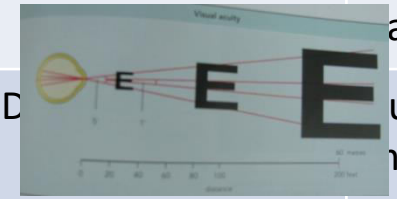

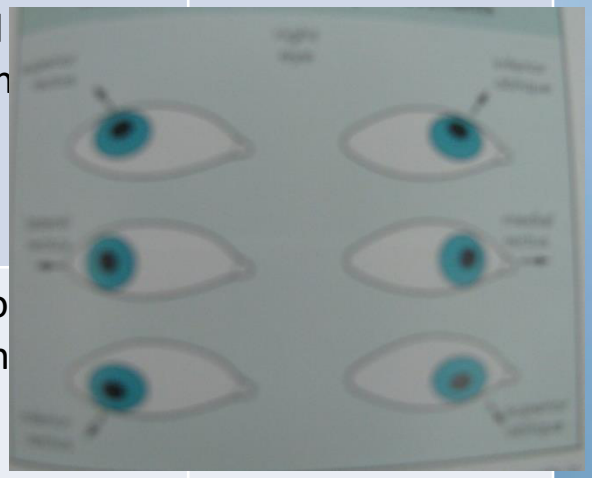

Abducent nerve	Eye movement	Double vision on lateral gaze	Moves eyes laterally	Failure of eye to abduct
Facial nerve	Facial movement	Lack of facial movement, eye closure Dysarthria	Facial contraction Smiling	Asymmetry of facial contraction
Auditory and vestibular nerve	Hearing Balance	Hearing loss Tinnitus Vertigo	Hearing test Nystagmus Balance	Decreased hearing Nystagmus Ataxia
Glossopharyngeal nerve	Palatal movement	Trouble with swallowing	Elevation of palate	Asymmetric palate
Vagus nerve	Vocal cords	Trouble swallowing	Vocal cords	Brassy voice
Spinal accessory nerve	Turns neck	None	Contraction of sternocleidomastoid and trapezius	Paralysis of sternocleidomastoid muscle
Hypoglossal nerve	Moves tongue	Dysarthria	Protrusion of tongue	Wasting and fasciculation or deviation of tongue

Facial Nerve

sensory

- Taste sensation from ant 2/3rd of tongue
- Distinguish between various taste sensation

Motor

- Muscles of facial expression
- Raise the eyebrows, close the eyes tightly, blow out the cheeks then purse the lips together & tighten the neck muscles





Eye & Ear Evaluation

EYE

- Questions regarding the vision and any recent changes
- Any diplopia or blurriness of vision is noted, as well as whether this relates to pain problem.

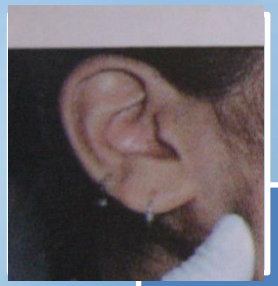

EAR

- Ear pain is the common source of facial pain
- Proximity to TMJ & muscles of mastication as well as their common trigeminal innervations frequently creates pain.
- Infection of the EAM: pushing inward the tragus causes pain

CERVICAL EVALUATION

- Cervicospinal & dysfunction can be referred to the orofacial pain.

- Test:
  - Examine the mobility of the neck for range of movements
  - Any pain or limitation of movement is recorded to determine whether it is muscular or vertebral

MUSCLE EXAMINATION

- Routine orofacial examination includes palpation of temporalis, masseter, sternocleidomastoid & posterior cervical.
- Classified as 4 categories:

A0 : No pain / tenderness on palpation

A1 : Uncomfortable on palpation

A2 : Definite discomfort / pain

A3 : evasive action or verbalizes a desire of not to be palpated again in that area.

TRIGGER POINTS

- Specific hypersensitive areas within the muscle tissue.
- A small, firm tight band of muscle tissue/ tendon is often felt.

- Types:
  - Active: hypersensitive to palpation, cause referred pain
  - Latent: tender to palpation but do not cause pain unless activated.

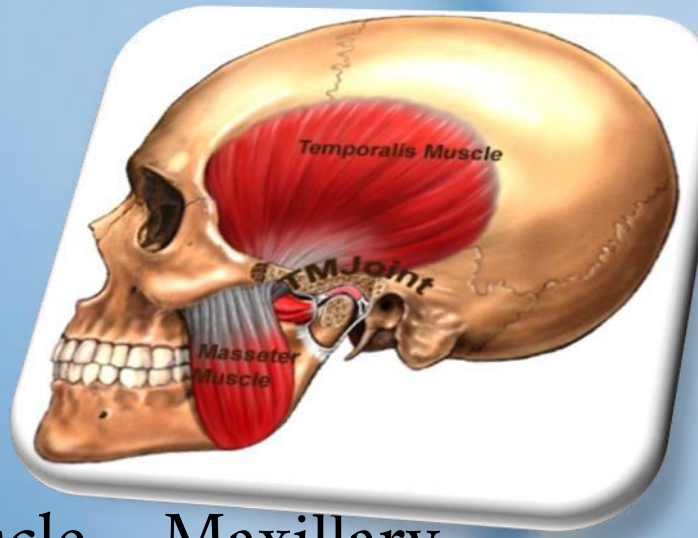

- Muscles involved:
- Superior belly of the Masseter muscle - Maxillary Posterior Teeth
- Inferior belly of the Masseter muscle – Mandibular Molar Teeth
- Anterior Digastric muscle – Mandibular Anterior Teeth
- Temporal muscle – Maxillary Anterior or Posterior Teeth

MASTICATORY EVALUATION

- Range of mandibular movements
- Tempromandibular joint evaluation

ORAL STRUCTURES

- INSPECTION:
  - Hyperemia, inflammation, abrasion, ulceration, neoplasm or other abnormality.

- Oral mucosa is tested by touch, pin-prick and manual palpation.

- Periodontal condition should be carefully evaluated.
- Radiographs – to identify changes in the alveolar bone support.

- Teeth :
  1. Sensitivity or tenderness without provocation
  2. Sensitivity or tenderness due to occlusal function
  3. Sensitivity to touch, percussion or probing with a dental explorer
  4. Tenderness from pressure directed down the long axis of the tooth
  5. Tenderness from pressure exerted laterally on the tooth
  6. Response to thermal shock
  7. Response to electric pulp tester
  8. Radiographic evidence of pathologic change
  9. Evidence of occlusal trauma

- Assessment of occlusal relationship between maxilla and mandible when masticatory pains are present

INVESTIGATIONS

- IMAGING:
  - Teeth, sinuses and TMJ
  - Thermography: crystals change color in response to temperature gradient, due to altered blood flow in superficial structures → neuropathic pain
- Laboratory testing:
  - Blood testing & urinalysis, patient's suspected of systemic illness.

DIAGNOSTIC ANAESTHESIA

- ‘Conduction anesthesia administered for the evaluation of etiology of painful conditions’.(Stedman)
- Topical anesthesia: for neuralgic trigger area
- Somatic nerve blocks: mandibular, mental, lingual, long buccal, palatal, incisive canal, posterior superior alveolar & infraorbital nerve block.
- Soft tissue infiltration: site of primary pain
- Intraligamentary / intra osseous : deeper pain
- Intracapsular : TMJ
- Intramuscular injections : myofacial trigger points.

OROFACIAL PAIN CLASSIFICATION

Table 7-2 Orofacial Pain Classification

Axis I (Physical Conditions)

I. Somatic pain
  A. Superficial somatic pain
    1. Cutaneous pain
    2. Mucogingival pain
  B. Deep somatic pain
    1. Musculoskeletal pain
      a. Muscle pain
        i. Protective co-contraction
        ii. Delay onset muscle soreness
        iii. Myofascial pain
        iv. Myospasm
        v. Myositis
      b. Temporomandibular joint pain
        i. Ligamentous pain
        ii. Retrodiscal pain
        iii. Capsular pain
        iv. Arthritic pain
      c. Osseous and periosteal pain
      d. Soft connective tissue pain
      e. Periodontal dental pain
    2. Visceral pain
      a. Pulpal dental pain
      b. Vascular pain
        i. Arteritis
        ii. Carotidynia
      c. Neurovascular pain
        i. Migraine with aura
        ii. Migraine without aura
        iii. Cluster headache
        iv. Paroxysmal Hemicrania
        v. Neurovascular variants
      d. Visceral mucosal pain
      e. Glandular, ocular, and auricular pain
Neuropathic pain
A. Episodic neuropathic pain
  1. Paroxysmal neuralgia
    a. Trigeminal neuralgia
    b. Glossopharyngeal neuralgia
    c. Geniculate neuralgia
    d. Superior laryngeal neuralgia
    e. Nervous intermedius
  2. Neurovascular pain (see visceral pain)
B. Continuous neuropathic pains
  1. Neuritis
    a. Peripheral neuritis
    b. Herpes zoster
    c. Postherpatic neuralgia
  2. Deafferentation pain
    a. Neuroma
    b. Atypical odontalgia
  3. Sympathetically maintained pain

Axis II (Psychologic Conditions)

I. Mood disorders
  A. Depressive disorders
  B. Bipolar disorders
  C. Mood disorders due to a medical condition
II. Anxiety disorders
  A. Generalized anxiety disorders
  B. Posttraumatic stress disorders
  C. Anxiety disorders due to a medical condition
III. Somatoform disorders
  A. Undifferentiated somatoform disorders
  B. Conversion disorders
  C. Pain disorders
  D. Hypochondriasis
IV. Other conditions
  A. Malingering
  B. Psychologic factors affecting a medical condition
    1. Personality traits or coping style
    2. Maladaptive health behavior
    3. Stress-related physiologic response
  C. Any other mental disorders not mentioned in this classification

DIAGNOSIS

Establishing the pain category

+

= DIAGNOSIS

With the help of the orofacial pain classification, six questions are categorized:

1)Is the pain Chronic / Acute

- Chronic pain : lasts longer than 6 months
  - Got greater possibility of psychologic factors(Axis II)
- Psychologic factors associated with chronic pain condition:

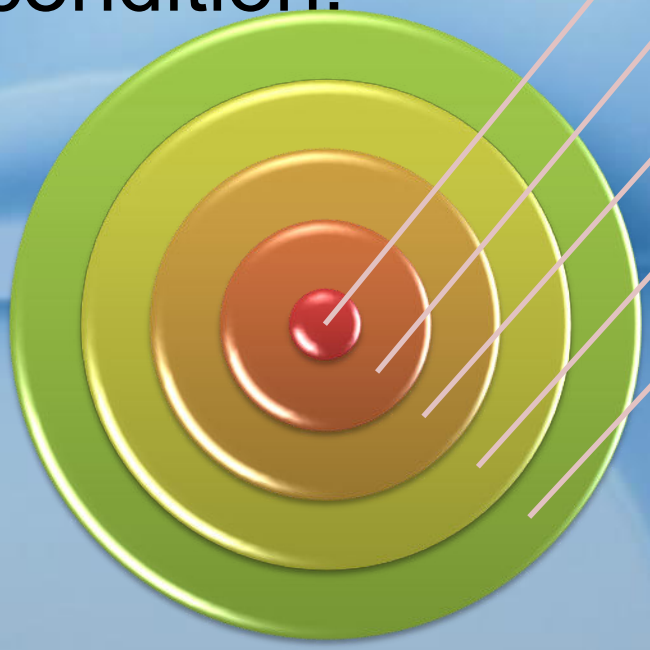

Progressive inadequacy of local cause

Progressive nonphysiologic behavior of pain

Withdrawal from normal daily activities

Progressive emotional &/ or physical deterioration

Mood changes (depression),

Evidence of anxiety & alterations in sleep pattern

2) Is the pain Neuropathic / Somatic

- Assuming that Axis II factors are not dominant features, the next diagnostic issue is whether the pain starts from somatic structures supplied by normal elements (Somatic pain) / from abnormal neural structures (Neuropathic pain)
- Characteristics of neuropathic pains are:

1. Burning type of pain that are spontaneous, triggered or ongoing and remitting.
2. Pains that occur disproportionately to the stimulus
3. Pains that are accompanied by other neurologic symptoms
4. Pains that are initiated / accentuated by efferent sympathetic activity in the area.

3) Is the pain Primary / Secondary

- Assuming that neuropathic pain is absent
  - True primary pain or secondary manifestation such as referred or secondary hyperalgesia

PRIMARY PAIN

1. Local provocation of the site of pain increases the pain
2. Can be arrested by local anaesthetic / analgesic blocking

SECONDARY PAIN

1. Local provocation of the site of pain does not increases the pain
2. Cannot be arrested by local anaesthetic / analgesic blocking

IS THE PAIN SUPERFICIAL OR DEEP?

SOMATIC PAIN

SUPERFICIAL	DEEP
Pain is a bright , stimulating sensation & localized	Pain is duller, more depressing sensation & well localized
Response to local provocation	Response to local provocation is less.
Arrested by topical anaesthetic	Exhibits secondary manifestations
	Arrested by analgesic blocking

Is the pain Musculoskeletal or Viscera?

Musculoskeletal

1. Pain is related to biomechanical function
2. Response to provocation is proportionate to the stimulus
3. Pain arises from muscles, bone, joints & ligaments.

Visceral

1. Pain is related to metabolic function
2. Non-responsive to provocation until a threshold level is reached.
3. Pain arises from blood vessels, glands, viscera & pulp.

Is the pain Inflammatory?

- *Clinical features:*
  - Signs of inflammation
  - Pain reflects the intensity, type, location and phase of inflammatory reaction
  - Pain follows an inflammatory time frame

DENTAL ORIGIN

NON-DENTAL ORIGIN

TYPES OF DENTAL PAINS

- Dental Pains of Pulpal Origin
  - ACUTE PULPAL PAIN
  - CHRONIC PULPAL PAIN
  - RECURRENT PULPAL PAIN
- Dental Pains of Periodontal Origin
- Tooth Pain from Deficient Central Inhibition

a. Acute pulpal pain

- Difficult to localize the source of the pain.
- Intermittent or continuous
- Objective evidence
- cause : noxious stimulation of the pulpal receptors.
- Pulpal inflammation as a result of bacterial agents - extension to the periodontal tissue

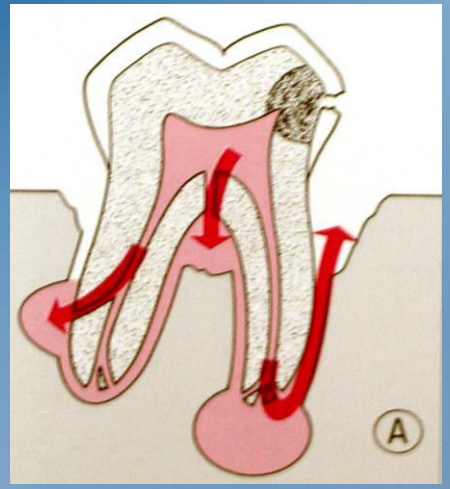

Inflamed dental pulp is hypersensitive to all stimuli - electric stimulation, thermal shock, probing, and percussion.

Range from hypersensitivity caused by sweets to spontaneous violent, throbbing pain of intolerable intensity.

Increased by both heat & cold, may relate to the contact of teeth & posture.

As the inflammatory process progress, spontaneous toothache may occur with no outside provocation.

- It may induce referred pains - anywhere in the face and head.
- If progresses to pulpal necrosis - pain from the pulpal tissue ceases.
- If the pulpal inflammation is sterile, a painless periapical granuloma or radicular cyst may develop.

CHRONIC PULPAL PAIN

- Injured pulpal tissue may progress from an acute to a chronic inflammatory phase
- Milder or asymptomatic unless further injury to it takes place.
- Respond to pulp testing

c. Recurrent pulpal pain

- Recurring periods of inflammation in a sequential pattern
- Occur when a partially split tooth is opened only by some unusual occlusal stress.
- Sensed as recurrent hypersensitivity and associated with changes in vascular pressure or fluid balance
- Slightly inflamed and the lowered pain threshold

IDENTIFICATION OF PULPAL PAIN

- Tooth should be tested by
  - inspection, probing, palpation, percussion, thermal shock, and electric stimulation.
- To localize the source of pain :
  - Systematic analgesic blocking done, first to determine whether the pain site is maxillary or mandibular and then to more accurately identify the offending tooth or teeth.

2. Dental Pains of Periodontal Origin

- Deep somatic pain of the musculoskeletal type
- More localized & is identified by percussing the tooth laterally or axially.
- local cause : trauma, occlusal overloading or contact with an adjacent embedded tooth.

- Other causes :
  - preexisting chronic periodontal lesion, spread from pulpal inflammation, the maxillary antrum, or a spreading osseous infection.

3. Tooth Pain from Deficient Central Inhibition

- Conditions that alter the effectiveness of the endogenous antinociceptive system may permit ordinarily nonnociceptive impulses to be transmitted and felt as pain.

- Multiple toothaches without adequate local dental cause
- Complain of allodynia in other surrounding tissues

4. Toothaches of Non Dental Origin

- Heterotopic pains occur as secondary effects from central sensitization or excitation of the second-order neurons.

- Rules help in differentiating primary pain from a referred pain:

1. Local provocation of the site of pain does not increase the pain.
2. Local provocation of the source of pain increases the pain, not only at the source but also at the site.
3. Local anesthetic blocking of the source of the pain decreases the pain at the source as well as the site.

TOOTHACHES OF NON DENTAL ORIGIN

- Non-odontogenic dental pain of **musculoskeletal** origin
- Non-odontogenic dental pain of **neuropathic** origin
- Non-odontogenic dental pain of **neurovascular** origin
- Non-Odontogenic dental pain due to **cardiac** condition
- Non-odontogenic dental pain due to **sinus or nasal mucosal toothache**
- Non-odontogenic dental pain of **psychogenic origin** - (Idiopathic pain disorder).

Muscular toothache

- The Masseter and temporalis muscles are the chief offenders

The clinical characteristics of a muscular toothache are as follows:

1. The pain is relatively constant, dull, aching, and non-pulsatile.
2. The pain is not responsive to local provocation of the tooth.
3. Examination reveals the presence of localized firm, hypersensitive bands within the muscle tissues (trigger points).

4. The toothache is increased with function of the involved muscle.
5. Palpation and provocation of the trigger points increase the toothache.
6. Local anesthesia of the tooth does not affect the toothache.
7. Local anesthesia of the involved muscle reduces the toothache.

Neurovascular toothache



- Migraines, both with and without aura cause pain.

characteristics :

1. The pain may be spontaneous, variable, and pulsatile—characteristics that simulate pulpal pain.
2. The pain is usually very intense.
3. The toothache is characterized by periods of total remission between episodes (like migraine pain).
4. The episodes of pain may pose a temporal behavior, appearing at similar times during the day, week or month.

5. The pain may actually undergo remission following dental treatment, although recurrence is characteristic with neurovascular pains.
6. If the pain experience is protracted, it may induce autonomic effects.
7. The patient reveals a history of other neurovascular disorders.
8. A trial of an abortive migraine medication reduces the toothache.



CARDIAC TOOTHACHE

- The pain is a deep, diffuse toothache that may sometimes pulsate.

- The toothache has a temporal behavior that inc with physical exertion or exercise.

- The toothache is associated with chest pain, anterior neck pain, and/or shoulder pain.

- *The symptoms of the toothache decrease after administration of nitroglycerin tablets.*
- *A complete health history is essential*
- *When a cardiac toothache is suspected, an immediate referral to proper medical personnel is mandatory.*

Neuropathic toothache

- Episodic or Continuous

Episodic neuropathic toothache

- severe, unilateral, lacenating and shock-like and is felt in a tooth.
- provoked by relatively innocuous peripheral stimulation of a "trigger zone."
- pain-free periods between the episodes of pain.
- Local anesthetic at the trigger point will reduce the episodes of paroxysmal pain.

Continuous neuropathic toothache

- Neuritic pains and Deafferentation pains

- Neuritic pain / neuritis arises from an inflammatory response of the nerve.
- persistent, nonpulsatile, often burning pain felt in a tooth.
- accompanied by other neurologic symptoms
- The associated gingival tissue may be affected.
- The onset of the toothache followed by infection or trauma

Deafferentation toothache :

- continuous but often varies in intensity.
- maxillary canines and premolars.
- middle-aged women with a history of trauma.
- not changed by local provocation.
- effect of local anesthesia is unpredictable.
- not responsive to dental therapies.

atypical odontalgia:

- Pain in a tooth or tooth site
- Continuous or almost continuous pain
- Pain persisting more than 4 months
- No sign of local or referred pain
- Equivocal results of a somatic block

Sinus Or Nasal Mucosal Toothache

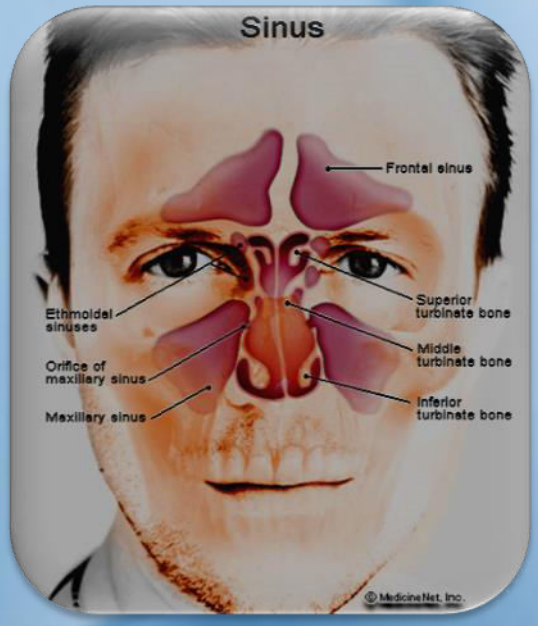

- Referred pain – maxilla & maxillary teeth
- Feeling of pressure below the eyes.
- Increased
  - application of pressure over the involved sinus
  - lowering the head
- Tooth - sensitive to percussion.
- Local anesthesia of the tooth does not eliminate the pain.

Neuralgia Inducing Cavitational Osteomyelitis/Osteonecrosis - (NICO)

- Hypothesis that certain forms of chronic orofacial pain are caused by cavitation defects in the mandible or maxilla, a condition called NICO.

- Propose etiology is chronic inflammation or necrosis from bacterial osteomyelitis or vascular pathosis following extraction.

Ratner E, 1979 - Jawbone cavities and trigeminal facial neuralgias

Psychogenic Toothache

- many teeth and/or other sites.
- The pain jumps from tooth to tooth or to other locations.
- There is a general departure from normal or physiologic patterns of pain.

- There is an unusual and unexpected response to therapy.
- The toothache is chronic and often unchanging.
- There is no identifiable source of pain, and the clinical characteristics do not fit any of the other pain conditions.

Cardinal warning symptoms of nondental toothache

- Spontaneous multiple toothaches
- Inadequate local dental cause for the pain
- Stimulating, burning, nonpulsatile toothaches
- Constant, unremitting, nonvariable toothaches
- Persistent, recurrent toothaches
- Failure of the toothache to respond to reasonable dental therapy

MUSCLE PAIN

Emanates from skeletal muscles, tendons & fascia.

Cause : trauma, overstretching, ischemia & hyperemia.

Nonpulsatile,variable,dull aching, tansitory / permanent

Relates to biomechanical stimulation

Graduated response – proportionate to stimulus

Co-contraction

Muscle soreness

Myofacial pain

Myospasm

Myositis

MYOFACIAL PAIN

- Regional myogenous pain characterized by local areas of firm, hypersensitive bands of muscle tissue known as trigger points

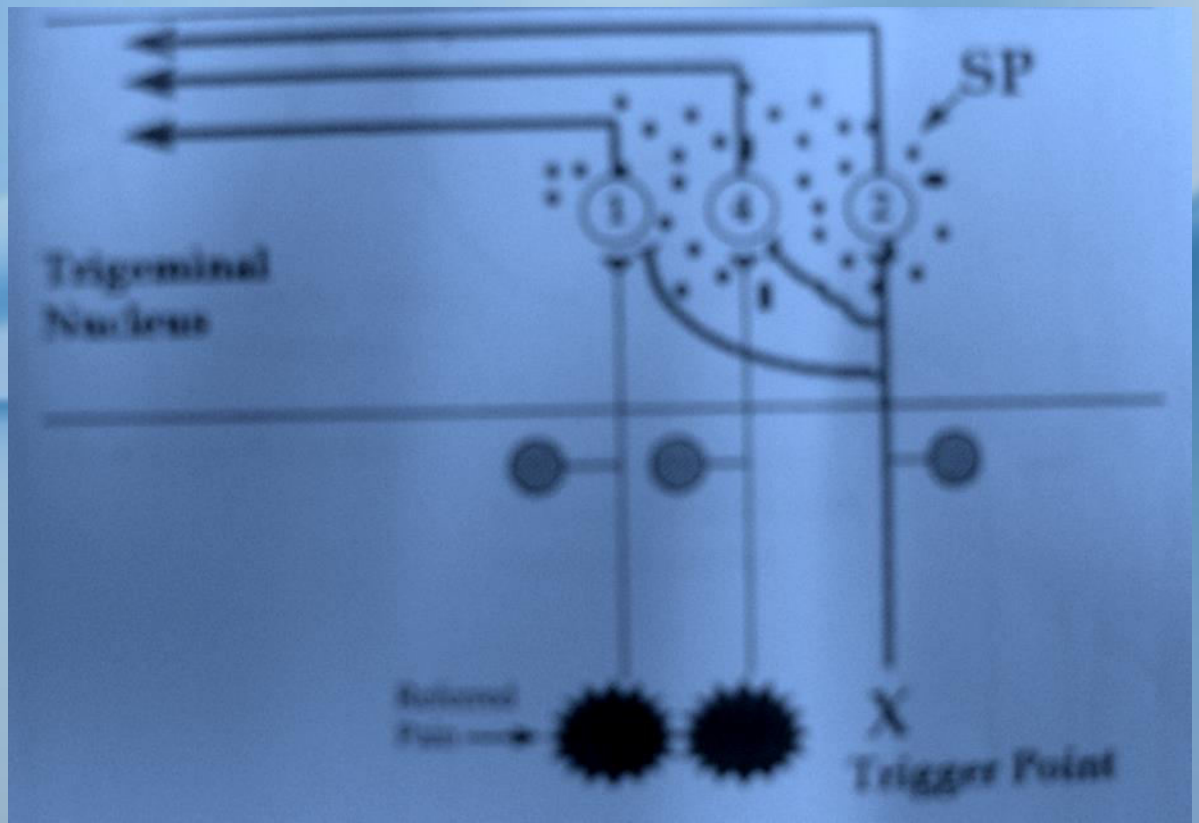

- A symptom complexing of pain, muscle tenderness, clicking in the joint & limitation or alteration of mandibular movement
- Regional pain, usually dull
- Localized tenderness in firm bands of muscle
- Reduction in local i.m injection

Laskin's criteria

- Unilateral dull pain in the ear or preauricular region - worse on awakening
- Tenderness of one or more muscles of mastication on palpation
- Limitation or deviation of mandible on opening

Other features

- Lateral pterygoid & masseter
- Signs of bruxism – tooth wear, mobility, hypertrophy of muscles , widening of PDL – x ray

TMJ PAIN

LIGAMENTOUS

- Intermittently in conjunction with disc interference & condylar translatory movements
- Dysfunction : Interference during mandibular movements

RETRODISCAL

- ↑ clenching in maximum interception & forced ipsilateral excursive movement of the mandible
- Decreased by biting against the separator
- Dysfunction : displayed as acute malocclusion

CAPSULAR

- Palpable tenderness directly over the condyle
- Increased : translatory movements
- Dysfunction : restricted mandibular movement

ARTHRITIC

- Increased – biting pressure, fast & forced movement, decreased – biting against a separator on ipsilateral side
- Dysfunction – restricted movement, interference during movements & acute malocclusion

VISCERAL PAIN

- 3 groups: pulpal pain, vascular pains of mouth & face and others like glandular, ocular & auricular in origin.
- Stinging & burning quality, protracted visceral pain tend to provoke vasomotor effects.

- Glandular pain:
  - Inflammatory
  - Distension & compression may accentuate
  - Salivary gland pain increases at mealtime
  - Submandibular : accentuated by chewing & swallowing

NEUROPATHIC PAIN

- Abnormality to neural components rather than to noxious stimulation.

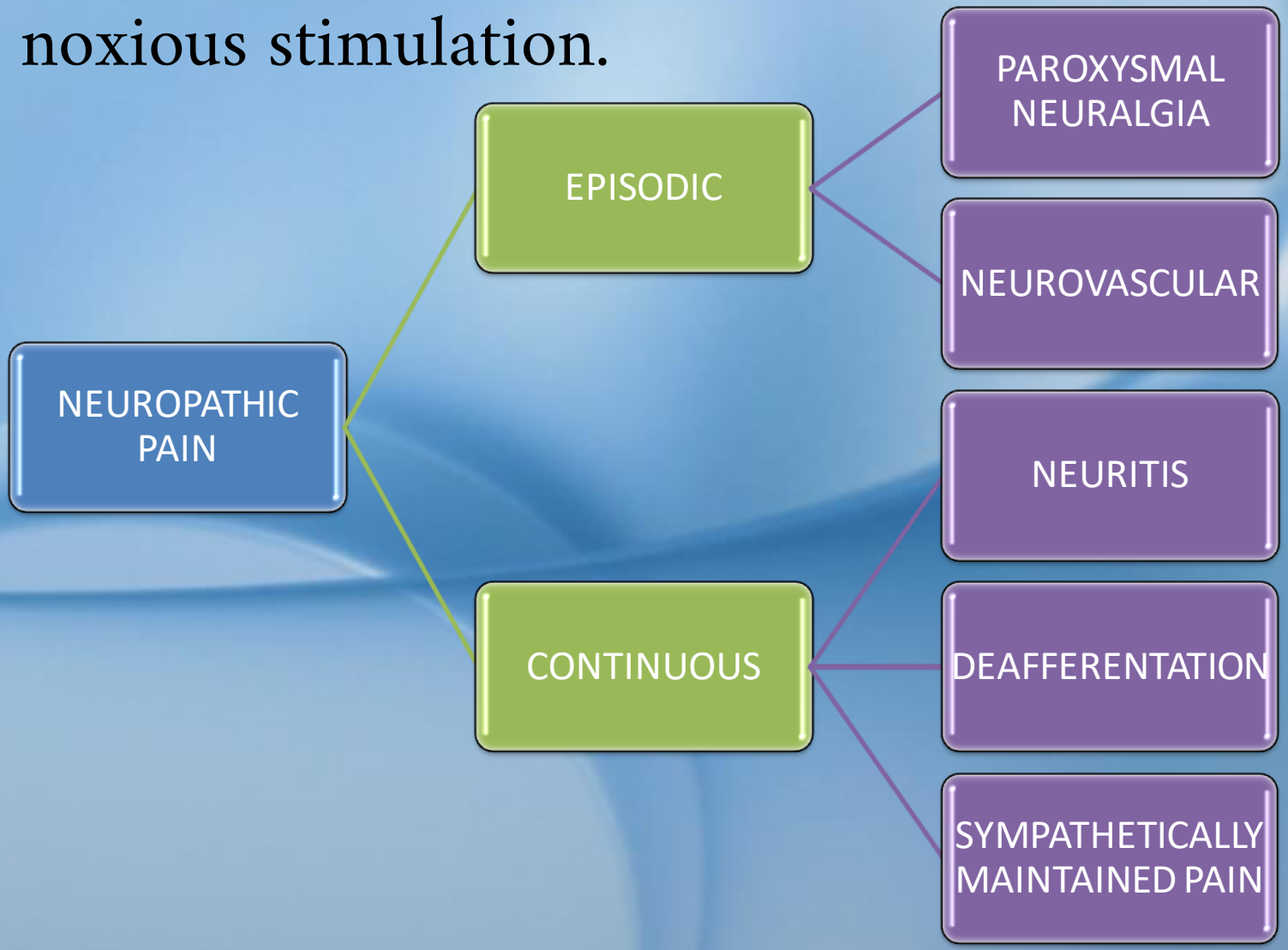

Episodic neuropathic pain

- Periods or very intense pain followed by total remission.
- Lasts for seconds to hours
- Well localizable, response to provocation if unfaithful.
- Neuralgic :
  - Bright, stimulating, burning quality, paroxysmal, extremely intense but rarely lasts more than 20-30 secs
  - Between episodes absence of pain, it is categorized according to types of nerves involved

Continuous neuropathic pain

- Interference with the normal transmission of afferent impulses by primary sensory neurons
- Burning sensation, persistent, ongoing, unremitting, fluctuation in intensity but no periods of total remission
- presence of other neurologic complaints : hyperesthesia, hypoesthesia, anesthesia, paresthesia, muscular tics, weakness, and paralysis, autonomic and special sense aberrations.

TRIGEMINAL NEURALGIA

- sharp, stabbing pain along with the distribution of trigeminal nerve
- Patients often clutch at the face and may experience spasmodic contractions of facial muscles during attacks, so it is called '**tic douloureux**' (painful jerking).

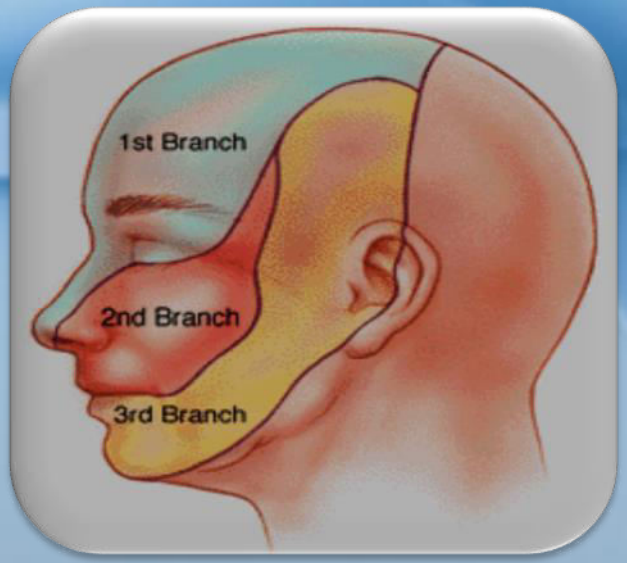

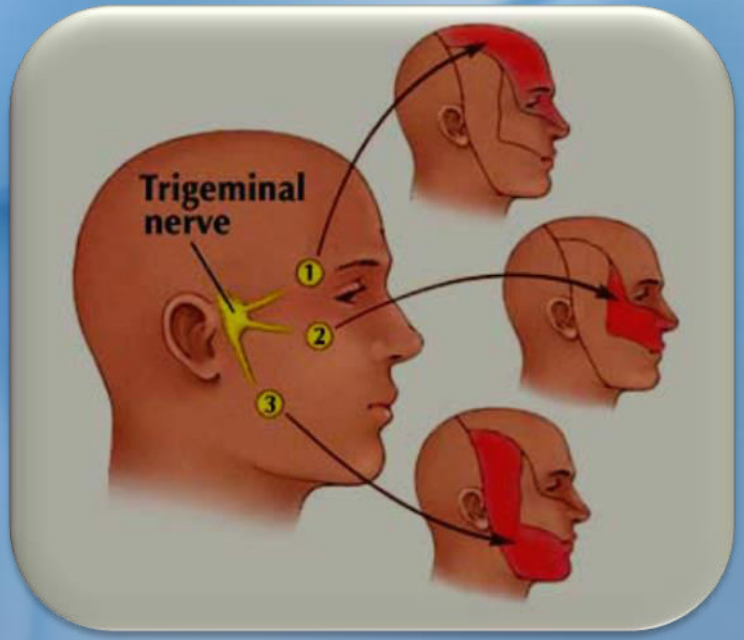

Clinical Features

- Recurrent episodes of intense shooting, stabbing, lancinating pain
- Lasts for few seconds & completely disappears
- Pain
  - electric shock like
  - unilateral
  - Precipitated by light touch of 'Trigger Zones' (nasolabial fold, corner of lip, ala of nose, cheeks & around the eyes)
  - Shaving, showering, eating, speaking or exposure to cold wind trigger a painful episode
- Refractory period – after attack touching trigger zone will not precipitate pain
- Maxillary branch – common
- Mandibular & ophthalmic branch
- Diagnosis **by local anesthetic blockade**

Glossopharyngeal neuralgia:

- Paroxysms of pain in tongue, soft palate/ tonsil are triggered by swallowing, chewing / protruding the tongue.
- Pain triggered – chewing, talking, swallowing
- Vagal symptoms –syncope & arrhythmia
- confused with geniculate neuralgia, TMDs

- Diagnosis – application of topical anesthetic to pharyngeal mucosa – eliminates pain

CONCLUSION

- As orofacial pain is the presenting symptom of a broad spectrum of diseases, the dentist assumes a great responsibility for the proper diagnosis and management of pain in and around the mouth, face and neck.

REFERENCES

- Bells orofacial pain: The clinical management of orofacial pain – 6th edition
- Burket's Oral Medicine – 11th edition
- Concise medical physiology, Chaudhuri – 2nd edition
- The dental pulp. Biologic considerations in dental procedures – 3rd edition
- Oral pathology, clinical pathologic correlations, Regezi, Sciubba, Jordan – 5th edition
- Oral and maxillofacial pathology, Neville, Damm, Allen, Bouquot – 2nd edition
- Dent Clin N Am 51 (2007) 45–59 Central Mechanisms of Orofacial Pain-Robert L. Merrill, DDS, MS

- Dent Clin N Am Oct (1992) A clinical approach to the diagnosis of facial Pain-Antonia Balciunas, Michael A.Siegel, Edward G.Grace
- Dent Clin N Am 2 (1997) 155-185 History and Examination of the orofacial pain patient – Andrew S.Kaplan, DMD
- Dent Clin N Am (1991) Chronic Orofacial Pain-Richard A. Pertes, Gary M. Heir
- Dent Clin N Am (1991) 141–152 Diagnostic anaesthesia – Sheldon Gerald Gross